

INTRODUCTION

In 1928, Dr. Charles Pincus, a pioneer in cosmetic dentistry, created temporary porcelain and acrylic veneers for Hollywood stars. Thirty years later, Dr. Michael Buonocore discovered the acid etching technique to improve bonding resin to enamel surfaces. With the combination of both breakthroughs and the rise of social media, obtaining “the Hollywood smile” has become one of the most desirable and doable procedures in today’s day and age.

One of the most common reasons that patients may seek dental care is for discolored anterior teeth. The etiology of discoloration can occur from extrinsic factors (ex: food dyes such as coffee/wine/tea, tobacco, plaque and calculus accumulation) or intrinsically (ex: congenitally - dental fluorosis, dentinogenesis imperfecta, or acquired - tetracycline staining, trauma). With the emphasis of minimally invasive dentistry, there are different techniques such as **microabrasion, resin infiltration, bleaching, and veneers** used to preserve precious enamel to get the results one may be looking for.

ENAMEL MICROABRASION

Enamel Microabrasion is one conservative technique using acidic and abrasive products to improve discoloration limited to the outer enamel layer. This procedure results in removal of approximately 25-200 micrometers of enamel. Results are dependent on the number of applications and acid concentration used. If stains are deeper and penetrate the dentin layer, this method alone is not sufficient and may need a combination of resin filled infiltration and bleaching to achieve esthetic results.

Method: use a fine-tapered diamond bur with water to remove superficial staining. Rubber dam, patient goggles, and apply microabrasive product (ex: 18% hydrochloric acid and pumice, 6.6% hydrochloric acid with silica particles, or 37% phosphoric acid gel with extra fine grain pumice) 3x on each tooth for 60 second intervals with a rubber cup and brush bristles on very slow speed and high torque. Spray water and air during intervals. Polish with fluoride prophylaxis paste and apply 2% neutral pH sodium fluoride gel for 4 minutes. Three long-term case reports with 11, 20, and 23 year follow-ups shown in Figures 2, 3, 4.

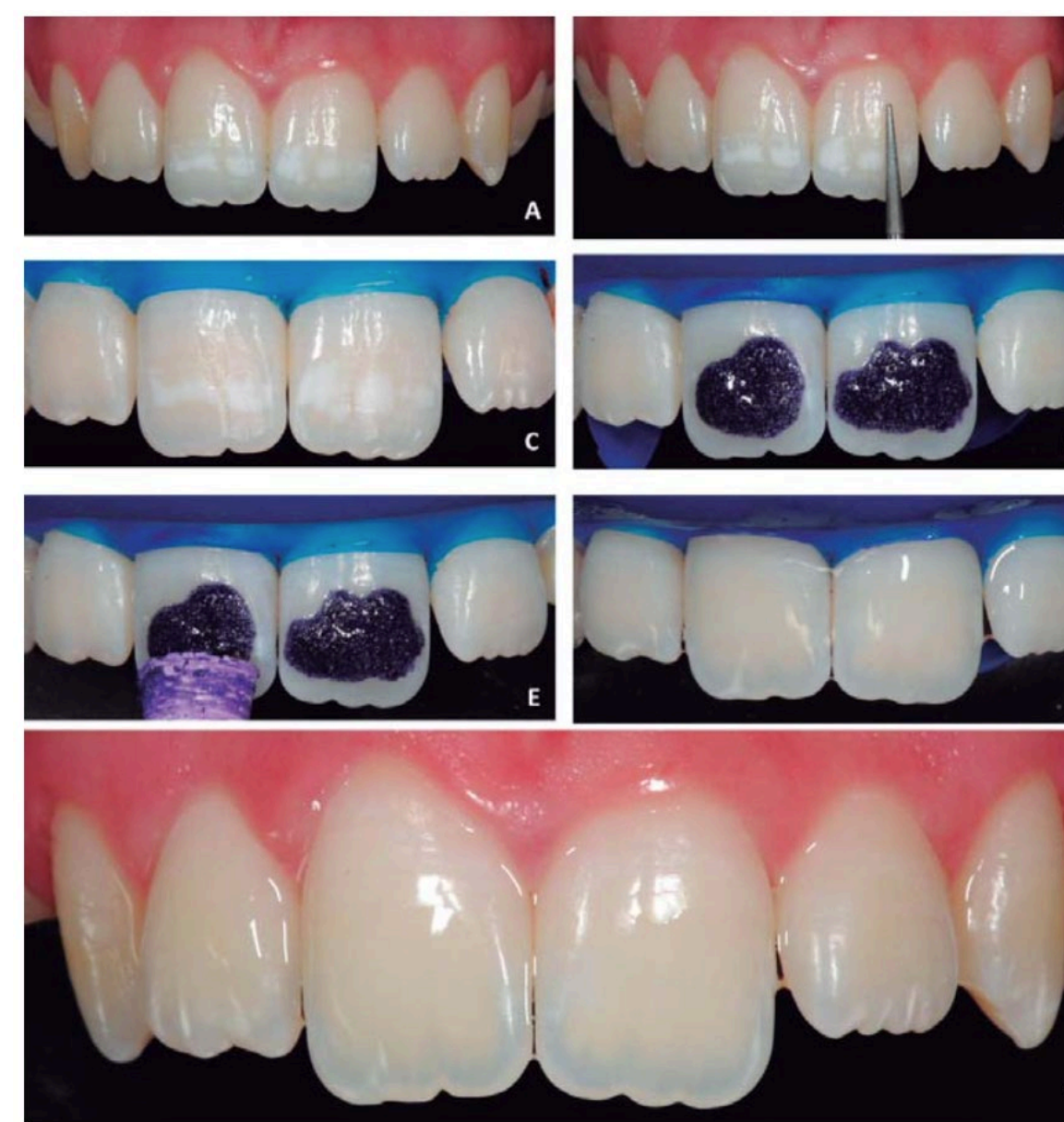

Figure 2- A: A 12-year-old girl had idiopathic white enamel demineralization of both the maxillary and mandibular teeth; B: The teeth are shown eleven years after the enamel microabrasion. The worn mesial and incisal surfaces of the maxillary central incisors were reconstructed with composite resin, shades A1 and A2

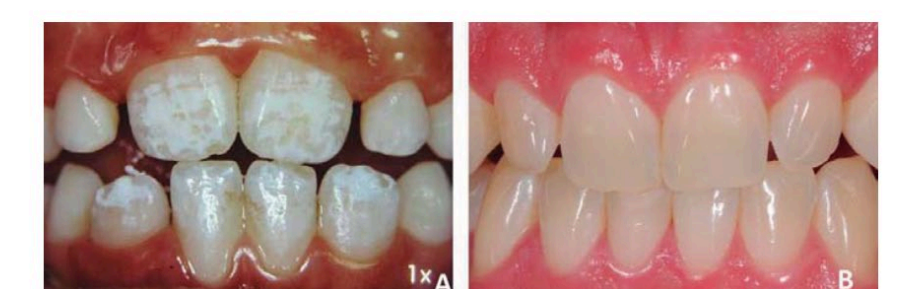

Figure 3- A: A 9-year-old boy with white enamel demineralization staining of six incisors; B: Twenty years after removal of the white stains on the maxillary central incisors by application of 18% hydrochloric acid and pumice; and after removal of white stains located on the mandibular teeth by application of the PREMA compound. The right mandibular lateral incisor presented a deep white stain; it was restored with resin-based composite

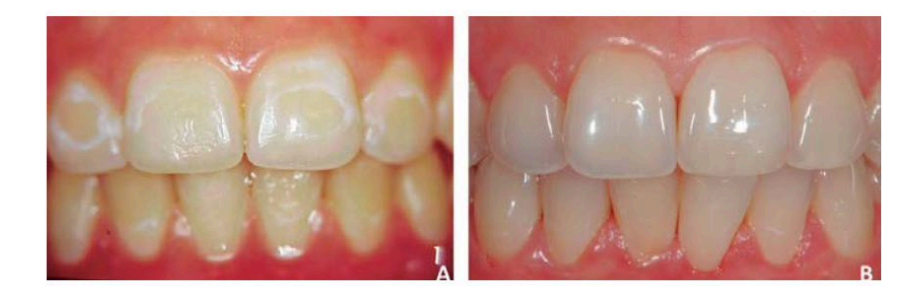

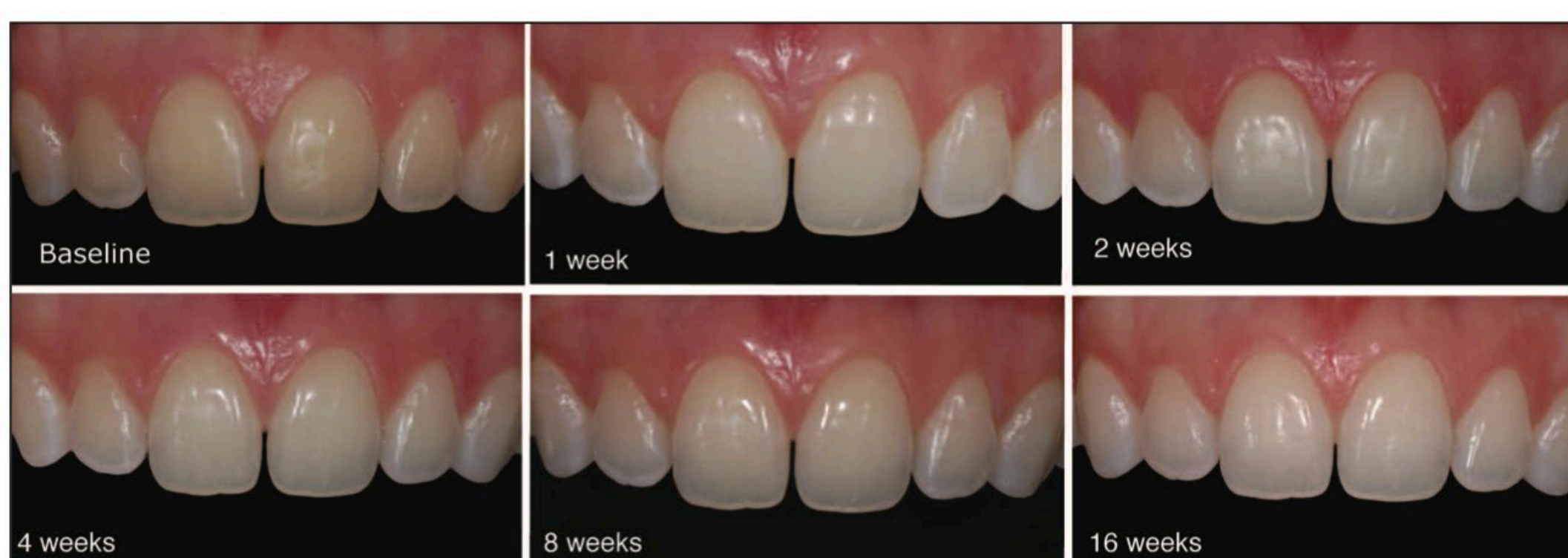Figure 4- A: Post-orthodontic white enamel stain of hard texture seen in a young patient; B: 23 years after the removal of stains using 18% hydrochloric acid/pumice and dental bleaching with 15% carbamide peroxide

BLEACHING

Oxidizing agents such as hydrogen peroxide (HP) or carbamide peroxide (CP) are used to penetrate the enamel layer into dentin to break down free radicals which react with pigmented organic molecules to reflect less color.

One clinical study performed 2 weeks of at-home bleaching with 10% CP vs. in-office bleaching with 35% HP (2 sessions, 3 applications for each session, 15 min per application) with and without light irradiation. Results showed a statistically similar degree of bleaching within the groups over 2 weeks and color stability over a 16-week period. Light source did not influence rate of bleaching and is not recommended from this study due to potential pulp damage.

Bleaching can be difficult to predict albeit 2+ shade improvement is possible. Color relapse and sensitivity are common side effects of bleaching. The concentration of peroxide and duration of application can vary results. It is recommended to bleach 2 weeks before final restorative placement for the best color shade match.



RESIN INFILTRATION

Resin infiltration arrests incipient enamel caries lesions by using low viscosity resin to penetrate enamel and obstruct the diffusion pathways for acids and dissolved materials as well as mechanically strengthen the breakdown of enamel. Typically adhesives and fissure sealants act as diffusion barriers, but in one study, a low viscosity resin with high penetration was developed to arrest incipient caries on post-orthodontic decalcifications or developmental defective enamel. This technique is indicated for inactive lesions with smooth, hard surface white spot lesions.

Method: Use 15% hydrochloric acid for 120 seconds on the surface layer, rinse for 30 seconds, air dry and use ethanol for 30 seconds to remove microporosity of lesion and allow resin to penetrate by capillary forces. Use infiltrative resin (ex: ICON) for 3 minutes. Wipe away excess and light cure for 40 seconds. Repeat ICON for 1 minute to accommodate for shrinkage, light cure for 40 seconds. Polish using resin-polishing discs. The results are more immediate than fluoride remineralization and color differences were noted between white spot lesions in both post-ortho and developmental defective enamel.

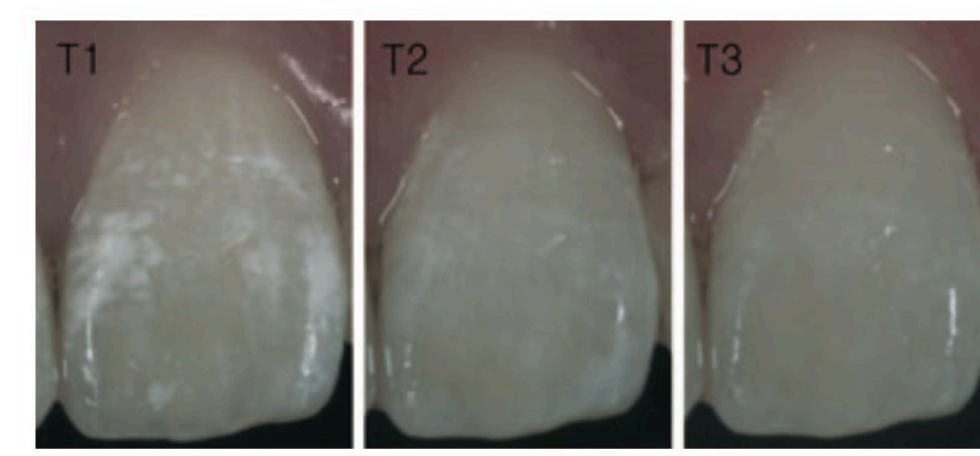


Fig. 1. Type 1 colour changes in a maxillary left central incisor with developmental defect of enamel. Compared to the T1 images (before treatment), enamel colour had recovered considerably in T2 (immediately after treatment) and further in T3 (1 week after treatment) appearing almost normal.

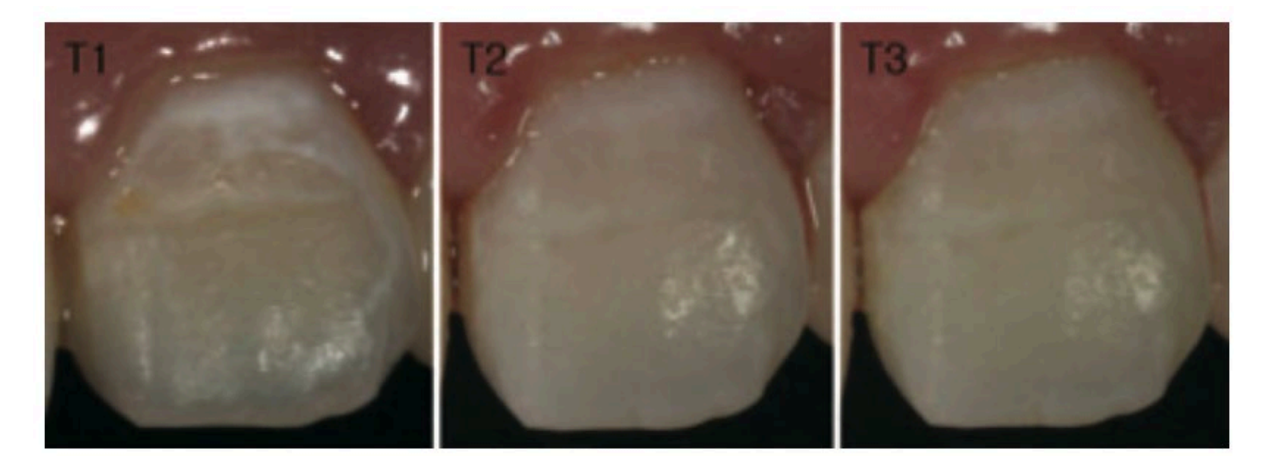
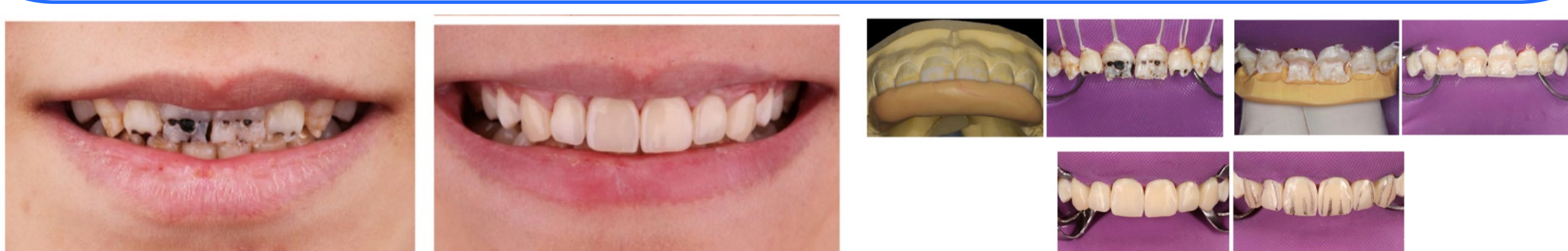


Fig. 3. Type 1 colour changes in a maxillary left lateral incisor with an orthodontic decalcified lesion. Compared to T1 (before treatment), the enamel colour had recovered considerably in T2 (immediately after treatment) and further in T3 (1 week after treatment), appearing almost normal.

VENEERS

Veneers use adhesive and restorative dentistry to emulate natural dental tissue in the anterior area. Additionally to discoloration, veneers are indicated for fractured or chipped teeth, abnormal tooth morphology such as peg laterals, correcting diastema or minor malpositions. The most popular esthetic ceramic for veneers is porcelain. An alternative material is with composite resins (Figure 1 showing a case report with a 2 year successful follow-up). Porcelain veneers requires minimal tooth prep, has excellent compressive, tensile, and shear strength when bonding, and is biocompatible to gingival tissue and periodontium.

One systematic review and meta-analysis of feldspathic porcelain and glass-ceramic veneers indicated an overall survival rate of 89-94%. A systematic review concluded that feldspathic porcelain veneers have a 10-year survival rate of 95%. The most common reason for failure is chipping/fracture as well as debonding. Some cons of this procedure is multiple visits, lab costs and chair time, fragility of ceramic, non-reparable and irreversible. Severe stains and crowding, poor oral hygiene, parafunctional habits are contraindicated for veneers.



REFERENCES

- Azer SS, Hague AL, Johnston WM. Effect of bleaching on tooth discoloration from food colourant in vitro. J Dent. 2011 Dec;39 Suppl 3:e52-6. doi: 10.1016/j.jdent.2011.09.006. Epub 2011 Sep 19. PMID: 21958473.
- Bernardon JK, Sartori N, Ballarin A, Perdigão J, Lopes GC, Baratieri LN. Clinical performance of vital bleaching techniques. Oper Dent. 2010 Jan-Feb;35(1):3-10. doi: 10.2341/09-008CR. PMID: 20166405.
- Joiner A. The bleaching of teeth: a review of the literature. J Dent. 2006 Aug;34(7):412-9. doi: 10.1016/j.jdent.2006.02.002. Epub 2006 Mar 29. PMID: 16569473.
- Kim S, Kim EY, Jeong TS, Kim JW. The evaluation of resin infiltration for masking labial enamel white spot lesions. Int J Paediatr Dent. 2011 Jul;21(4):241-8. doi: 10.1111/j.1365-263X.2011.01126.x. Epub 2011 Mar 14. PMID: 21401750.
- Korkut B. Smile makeover with direct composite veneers: A two-year follow-up report. J Dent Res Dent Clin Dent Prospect. 2018 Spring;12(2):146-151. doi: 10.15171/joddd.2018.023. Epub 2018 Jun 20. PMID: 30087767; PMCID: PMC6076883.
- Layton DM, Clarke M, Walton TR. A systematic review and meta-analysis of the survival of feldspathic porcelain veneers over 5 and 10 years. Int J Prosthodont. 2012 Nov-Dec;25(6):590-603. PMID: 23101039.
- Morimoto S, Albanesi RB, Sesma N, Agra CM, Braga MM. Main Clinical Outcomes of Feldspathic Porcelain and Glass-Ceramic Laminate Veneers: A Systematic Review and Meta-Analysis of Survival and Complication Rates. Int J Prosthodont. 2016 Jan-Feb;29(1):38-49. doi: 10.11607/ijp.4315. PMID: 26757327.
- Paris S, Meyer-Lueckel H. Masking of labial enamel white spot lesions by resin infiltration—a clinical report. Quintessence Int. 2009 Oct;40(9):713-8. PMID: 19862396.
- Serraglio CR, Zanella L, Dalla-Vecchia KB, Rodrigues-Junior SA. Efficacy and safety of over-the-counter whitening strips as compared to home-whitening with 10% carbamide peroxide gel—systematic review of RCTs and meta-analysis. Clin Oral Investig. 2016 Jan;20(1):1-14. doi: 10.1007/s00784-015-1547-8. Epub 2015 Aug 7. PMID: 26245272.
- Sundfeldt RH, Sundfeldt-Neto D, Machado LS, Franco LM, Fagundes TC, Briso AL. Microabrasion in tooth enamel discoloration defects: three cases with long-term follow-ups. J Appl Oral Sci. 2014 Jul-Aug;22(4):347-54. doi: 10.1590/1678-775720130672. PMID: 25141208; PMCID: PMC4126832.